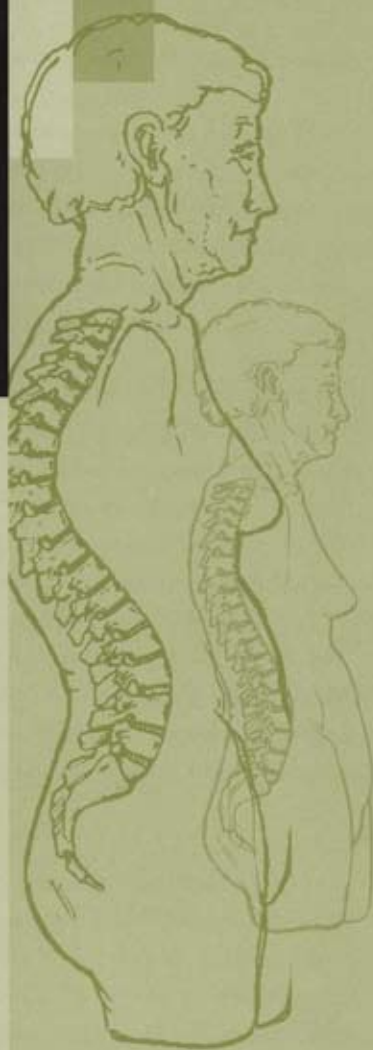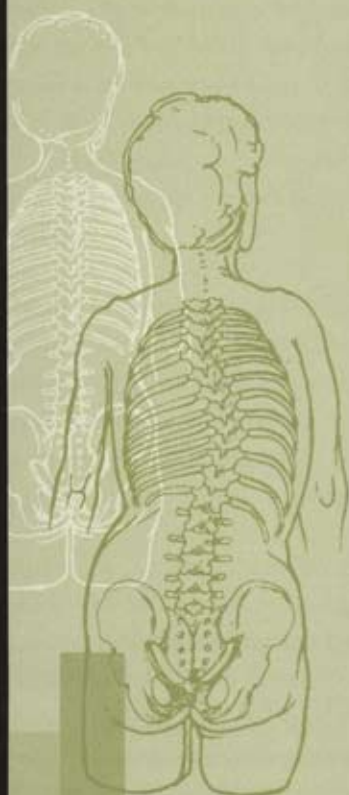


The Aging Spine

A Handbook for
Patients



Published by:
**Scoliosis
Research
Society**

The Scoliosis Research Society provides information in this brochure as a public service. The SRS believes that patients should contact their treating physician about the relevance of any information listed in this brochure prior to proceeding with any particular treatment. Just as no two individuals are exactly alike, no two patients with a spinal deformity are the same. Therefore, your spinal deformity surgeon will be the most important source of information about the management of your particular spinal problem.

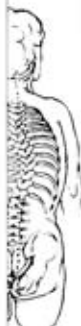Osteoporosis and Compression Fractures

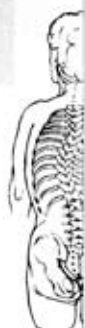Osteoporosis is a decrease in bone mass, more commonly seen in women in the post-menopausal period. It is a decrease not only in the mineral component, but also in what is called the organic component of bone. The extent of the osteoporosis can only be estimated on plain x-rays and must be confirmed by specific bone density tests or, in some cases, by bone biopsy to confirm its presence. About 15-20 million people have osteoporosis and over one half million suffer spinal fractures due to osteoporosis each year. These fractures can occur with minimal trauma or no trauma at all.

Back pain is the most common presenting symptom of this condition and x-rays may show wedge or compression fractures of the vertebrae. MRI or CT scans may be necessary for further evaluation of these fractures. Fortunately, most of these are successfully treated with just medications to control the pain, but the underlying osteoporosis should also be addressed once it is recognized. The treatment of osteoporosis itself is rapidly evolving. Current measures include combinations of calcium, vitamin D and estrogen. Calcitonin is used in some cases to inhibit bone resorption and fluoride has also been tried in an attempt to increase bone mass. More recently, drugs like fosomax, one member of the *bis*-phosphonate family of drugs which help to maintain and possibly increase bone mass, have been used in the treatment of osteoporosis.

In addition to medications, other things that help control pain and prevent worsening deformity are devices like certain kinds of back braces. Although these usually do not correct the wedging of the bone, they do support the spine and may decrease secondary muscle spasm. In rare cases, surgical treatment may be necessary to control the pain, improve the deformity, or decompress the nerve roots or spinal cord.

New techniques to treat the problem of compressed vertebrae include procedures like vertebroplasty and kyphoplasty. In these two techniques the vertebrae are injected with a bone cement (vertebroplasty) to improve the strength of the bone. Alternatively, cement can be injected after improving the wedging by inflating a balloon inside the vertebra body and filling the space with that cement (kyphoplasty). Both procedures require at least sedation and local anesthesia, but sometimes require general anesthesia





during their performance. The procedures are done percutaneously (using only very tiny incisions) using x-ray control. As with any other surgical procedures, there are certain risks inherent in performing these procedures. However, early results for these minimally invasive techniques are encouraging.

As a final thought, it is very important to confirm the diagnosis of osteoporosis rather than other possible conditions, such as infections, other metabolic bone diseases and benign or malignant bone tumors, prior to embarking on a course of treatment.

Osteoarthritis and Other Degenerative Conditions of the Spine

Degenerative discs and facet joints

Degeneration of the discs and the small joints of the spine (facet joints) is, generally a normal part of the aging process in the spine. The process as seen on x-rays may not cause any symptoms but can, in some individuals, be associated with significant back and/or leg pain. In those patients with advanced arthritis/degeneration, x-rays show marked narrowing of the discs as well as arthritic changes in the facet joints. Initial treatment is generally focused on improving muscle support of the back with exercises, the use of anti-inflammatory medications, and braces. If the initial pain is severe, a short period of bed rest may be necessary to control the acute pain, with gradual return of activities as soon as possible. Severe progressive symptoms associated with degenerative changes may require surgical treatment to alleviate the symptoms.

Spinal stenosis

As the arthritis/degeneration worsens, the spinal canal (the space which holds the spinal cord and nerve roots) can narrow as a result of these changes in the discs and facet joints, as well as thickening of one of the large ligaments that crosses the space between two vertebrae. These structures then press on the nerves in the spinal canal. This constriction, or stenosis, can lead to pain in the legs while walking and standing and is usually relieved by sitting or lying down. These kinds of symptoms are known as neurogenic claudication, which must be differentiated from the same kind of pain down the legs that is caused by circulatory problems, arthritis of the hips, or diabetic nerve

problems. Spinal stenosis is diagnosed specifically by CT or MRI scans. Sometimes EMG and nerve conduction tests are used to differentiate this condition from diabetic nerve involvement.

Nonsurgical treatment consists of anti-inflammatory medicines, exercise, physical therapy and occasionally steroid/local anesthetic injections. These injections can be into the soft tissues, such as the muscles and ligaments, into the spinal canal (epidural), or specific nerve root blocks. If these procedures do not relieve the symptoms then surgical decompression of the involved vertebrae may be necessary. This surgery is quite effective and allows patients to walk farther and stand longer. It involves decompressing the nerve roots by removing the roof of the spinal canal (laminectomy) and enlarging the spaces where the nerve roots exit the canal (foraminotomy). A fusion of the affected vertebrae may also be necessary if instability is present. Remember that a spinal fusion is a procedure which welds the spinal segments together using bone, either from the iliac crest (pelvis) or from the bone bank. In the majority of cases, a metal implant consisting of screws and rods is used to help maintain stability at these segments while the fusion heals.

The hospital stay is relatively short without fusion and a bit longer with it. In either case, particularly if a patient had some debilitation preoperatively, a short stay in a rehab facility, to regain strength and mobility, may be needed. The actual details of post-discharge care, resumption of normal physical and athletic activities, driving, and the possible use of a brace will be provided by the patient's surgeon based on specific issues of each individual's case.

Herniated lumbar disc

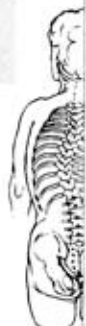Ruptured, slipped or herniated discs are terms that are commonly used for the same thing. Herniated discs most commonly occur in the 20 to 50 year old group, but can occur at all ages. In older patients, they may again be associated with arthritis and nerve root compression. Typically, most people will have an episode or two of low back pain not necessarily associated with a traumatic event and subsequently develop leg pain, commonly known as sciatica. Discs rupture and herniated because of degeneration and tears in various parts of the disc.

Symptoms are frequently self-limited and respond to restriction of activity, non-steroidal anti-inflammatory medications, short periods of bed rest, if the

The Aging Spine



The Aging Spine



pain is particularly severe, then exercise and physical therapy. If the symptoms do decrease, gradual return of full activities may take about four weeks. Although steroid medications that have been used to treat the sciatica in the past are still valuable drugs for this purpose, they are often associated with significant complications and should be used only briefly, if at all. In patients whose symptoms last longer than several weeks, who have significant and/or progressive leg weakness or loss of bowel/bladder function, an MRI scan or a CT scan with or without a myelogram should be performed to identify the abnormality

If there is no improvement within one to three months with non-operative measures or if leg pain or weakness persists or worsens, surgical treatment may be necessary. The most common procedure for this condition is a discectomy in which a small incision is made and the disc is removed. Relief of symptoms is frequently quite dramatic. Healthy patients undergoing this surgery can have it done as an outpatient procedure, but occasionally the side effects of anesthesia and pain medication used post operatively require admission to the hospital for a day or two. After the surgery, some recovery is necessary but gradual return to activities is the rule and is allowed in seven to ten days. Return to work and sports varies and should be discussed with the patient's surgeon.

Cervical Degenerated Disc Disease

Neck pain and stiffness frequently occur in the aging spine. This is due to arthritic changes in the joints and degenerated discs, which can be easily seen on regular x-rays. When the neck pain is associated with pain and/or numbness or weakness in the arm or hand, further workup may be needed as these symptoms indicate pressure on one or more nerve roots. Evaluation entails a thorough neurologic examination and imaging using an MRI and/or CT scan with or without a myelogram.

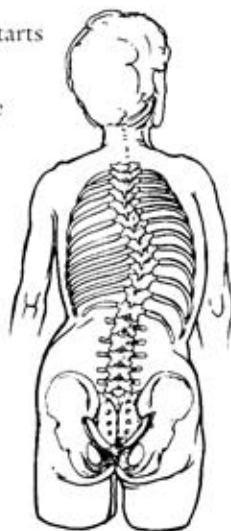Treatment consists of immobilization with a collar, non-steroidal anti-inflammatory medications, and physical therapy. Occasionally, halter traction is used to help as well. If the symptoms are significant and persistent despite these non-operative measures and/or a significant neurological deficit is occurring, then surgical treatment will be necessary. This generally entails what is called an anterior cervical discectomy and fusion, with possible removal of the degenerative bony spurs that occur around the border of the

discs. The fusion is performed with either iliac crest or bank bone and the vertebrae involved are fixed together using a plate and screws. If multiple levels are involved, a posterior decompression and stabilization with plates and screws and a fusion may be performed as an alternative. It should be recognized that if there is severe stenosis of the canal in the cervical spine, significant pressure on the spinal cord itself (not just the nerve roots) can occur and may lead to loss of the ability to walk and/or loss of bowel and bladder function and control. This is known as cervical myelopathy. When it occurs, it usually progresses slowly and diagnosis is often delayed. Decompression and stabilization are necessary if the spinal cord is being compressed.

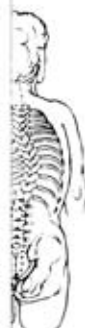Scoliosis and Other Spine Deformities

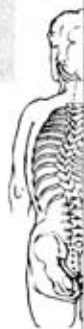Adult Idiopathic and Degenerative (de novo) Scoliosis

Scoliosis in the adult is a curvature of the spine that can occur for two reasons. The first is that it may be a residual (left over) scoliosis that started when the patient was younger (idiopathic scoliosis). The degenerative or *de novo* type is a form of scoliosis that starts after age 40 and is thought to be the result of arthritis or degeneration of the spine, with changes in alignment due to degeneration of the discs and the facet joints. It is known that some of the curves that start off in a growing child will worsen as an adult. It has been suggested that curvatures which are 50 degrees or more after skeletal maturity may worsen by about one degree a year. Curves of less than 30 degrees really don't worsen. This is otherwise known as the natural history, or what happens to the spine if no treatment is ever rendered. The *de novo* curves may also progress a few degrees a year, particularly if there is osteoporosis and a sequential collapse of the vertebrae.



Since both types can be associated with arthritis, many patients will have back pain and muscle fatigue, as well as possible leg pain. Larger curves (over 40 degrees) should be checked periodically for increases in curve size. Worsening of the scoliosis will cause loss of height along with the other





symptoms previously mentioned. Evaluation of the process involves the use of regular x-rays, MRI scans and possibly CT-myelograms. These studies help identify stenosis and other abnormalities in the spine and around the nerve roots and spinal cord that may be associated with the spinal deformity.

Treatment consists of arthritis medications such as non-steroidals for pain relief, physical therapy for improving overall function, and exercise to improve strength. If the medications and therapy do not work, cortisone/local anesthetic injections in the muscle, joints or spinal canal may be an option. Surgical treatment is frequently necessary if the curve or other symptoms worsen. The type of surgical procedure varies depending on the curve type and size and whether there is any associated spinal stenosis. The most common surgery is performed through the back (posterior) and consists of a spinal fusion with metal implants and bone graft (from the pelvis or the bone bank), with or without decompression of the nerve roots. Sometimes the surgery may need to be performed in the front of the spine (anterior) for better stability, correction and healing. Occasionally a combination of both anterior and posterior surgery is necessary to correct the problem. The hospital stay for such procedures depends on the type(s) of procedures done and the overall condition of the patient. Many adults undergoing scoliosis surgery smoke or have medical conditions that may affect healing and recovery time. A brace is frequently used after surgery. Details regarding return to normal physical and athletic activities, post-operative care and other issues should be discussed with the patient's surgeon.

Spondylolisthesis

Spondylolisthesis is a slippage of one vertebra on another. There are two common types. The most common form develops in childhood and is symptomatic in a teenager or in an adult who has developed it during teenage years. The second type is degenerative spondylolisthesis, caused by disc and joint deterioration. This form generally becomes noticeable in the 50 and older age groups. Both types may present with spinal stenosis or nerve root compression. People with spondylolisthesis may have back and sometimes leg pain. As the arthritis worsens, the spinal canal can narrow as a result of the enlarged facet joints, degenerated discs and enlarged ligaments, which causes pressure on the nerve roots and spinal cord in the spinal canal. These events can lead to leg pain while walking or standing. As mentioned earlier,

the cause of pain must be differentiated from circulation problems, arthritis of the hip or nerve problems associated with diabetes.

Generally, spondylolisthesis is diagnosed with regular x-rays. Nerve root compression is detected by the use of CT or MRI scans. EMG and nerve conduction tests may be needed to differentiate other diagnoses from spinal stenosis.

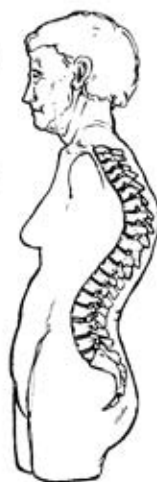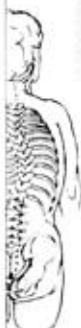Non surgical treatment consists of anti-inflammatory medicines, exercise and physical therapy, plus occasional injections as mentioned previously. If these measures fail and a patient continues to have significant symptoms, surgical treatment may be necessary. That involves decompressing the nerve roots and/or spinal cord by removing the roof of the spinal canal (laminectomy) and enlarging the spaces for the nerve roots (foraminotomy). A spinal fusion is performed, again using either iliac crest or bank bone. Correction of the slippage and/or maintenance of stability until the fusion heals is done via the use of metal implants.

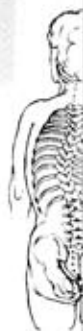Those patients requiring surgery need to be in the hospital for 4 or 5 days and, again, recovery and healing will be affected by the patient's general medical condition and smoking history. Details of post-operative care and resumption of activities should be discussed with the surgeon.

Kyphosis

Kyphosis is a forward bending of the spine, which produces a hump of the back or a roundback deformity. Some people have postural kyphosis, which is not rigid. Others will have a more rigid or structural type of kyphosis. Diagnoses such as pre-existing Scheuermann's kyphosis (which can be made worse by superimposed compression fractures) are frequently responsible for the production of this deformity. However, multiple compression fractures alone can produce the deformity due to collapsed vertebrae, as is commonly seen in older osteoporotic women. Methods of evaluation are regular x-rays, MRI and CT scans and myelograms.

Back pain is the most common presenting symptom, but patients may also complain of increasing deformity and loss





of height. Current treatment consists of pain medication, but if the patient has osteoporosis, treatment for this must be addressed as well. As mentioned previously, there are numerous medications now available for this purpose, which may improve the pain symptoms but cannot correct the wedged bone or a significant spinal deformity. Braces may support the spine and decrease muscle spasm. If there is any doubt as to the underlying cause of the compression fractures a biopsy may be necessary to rule out such things as tumors, infection or other conditions. If these conservative measures do not help, surgery may be necessary to control pain and improve deformity or decompress nerve roots. Vertebroplasty and kyphoplasty mentioned previously may be of value in these conditions, but more extensive fusions and instrumentations are often necessary to achieve treatment goals.

Summary

The normal process of aging causes various changes all along the spine, which may lead to one or more of the conditions discussed above. The prevention of osteoporosis with its subsequent complications is the mainstay of prevention against many, but not all, of these conditions. A number of these can be cause, or at least worsened, by the presence of weak vertebrae. Others are caused by the natural process of aging which can be superimposed on a pre-existing spinal condition. While pain in various areas of the spine may be a nuisance, neurologic problems like weakness and numbness require urgent and proper evaluation and treatment to prevent serious permanent loss of function. Maintaining a degree of physical fitness and muscle strength as well as preventing and/or treating osteoporosis will go a long way in managing the inevitable changes in the spine that occur with the normal aging process.

Scoliosis
Research
Society

555 East Wells Street
Milwaukee, WI 53202 USA
(414) 289-9107
Fax: (414) 276-3349

www.srs.org

Copyright © 2004, SCOLIOSIS RESEARCH SOCIETY

